

Varicocelectomy: microsurgical subinguinal technique is the treatment of choice

Armand Zini, MD

It is reported that 35% to 40% of infertile men have a palpable varicocele (dilated testicular veins), whereas the prevalence of a varicocele in the general male population is about 15%.¹⁻³ Although varicoceles have been associated with impaired male fertility potential, it is also clear that a significant proportion of men with a varicocele (about 75%) are fertile.^{2,4,5} As such, a cause and effect relationship between varicocele and male infertility has not been conclusively established.⁶ The effect of varicocelectomy on male fertility is also controversial.⁶⁻¹⁰ Uncontrolled studies have generally shown improved semen quality and pregnancy outcome after surgery.¹¹ On the other hand, the results of randomized controlled studies of varicocelectomy for clinical varicocele (only a few such studies are published) are equivocal.¹²⁻¹⁵

Despite the absence of clear evidence for a positive effect of varicocelectomy, many clinicians consider the data sufficient to support the practice of this surgery, and varicocele is the most commonly treated condition in men with infertility in North America.⁸ The benefit of varicocele repair must be balanced by the risk associated with the procedure itself. As such, it is important to select the procedure with the highest success and lowest complication rate. Also, it is important to consider assisted reproductive technologies (ARTs) as an alternative to varicocelectomy in infertile couples.¹⁶

Etiology of varicocele

The etiology of varicocele is multifactorial. The anatomic differences between the left and right internal spermatic vein (accounting for the predominance of left-sided varicocele), the incompetence of venous valves resulting in reflux of venous blood and increased hydrostatic pressure are the most popular theories.^{17,18} Increased intra-abdominal pressure during childhood and early adolescence may be a predisposing factor in the development of a varicocele.¹⁹

Mechanisms of varicocele-induced pathology

Scrotal and intratesticular temperatures are elevated in humans and in experimental animal models with varicocele, and varicocelectomy may reduce testicular temperature.²⁰⁻²⁴ Scrotal hyperthermia likely represents the primary factor by which a varicocele affects endocrine function and spermatogenesis, both sensitive to temperature elevation (testicular proteins exhibit a reduced thermal stability compared with proteins from other organs).²⁵⁻²⁷ The detrimental effect of hyperthermia may also be exerted on the epididymis.²⁸ Experimental elevations in epididymal temperature reduce the storage capacity of this organ, resulting in decreased sperm count and quality in the ejaculate.²⁸

Increased hydrostatic pressure in the internal spermatic vein from renal vein reflux may also be responsible for varicocele-induced pathology.²⁹

A key mission of our journal is to challenge readers with new concepts and provide new ideas and insights. To accomplish this mission, we have started this new section — Point / Counterpoint. This regular feature will highlight the most important debates in urology. The purpose of the section is to encourage vigorous and informed discussion on controversial issues in urology through the presentation of diverse opinions. We aim for a dispassionate discussion of controversies, recognizing that strong passions may exist in support of some positions.

Pathophysiology of varicocele

The adverse effect of varicocele on male fertility is most clearly manifested by the testicular atrophy generally associated with this condition.⁴ Using scrotal ultrasound, we objectively demonstrated that left testicular volume is less than right testicular volume in men with a left varicocele.³⁰

A varicocele is associated with bilateral spermatogenic abnormalities and Leydig cell dysfunction.^{31–35} The testicular histology in infertile men with varicocele is variable, but most studies report reduced spermatogenesis (hypospermatogenesis). The observed increase in germ cell apoptosis is thought to occur as a result of hyperthermia and low testosterone levels in the testicle.²⁶ Testosterone concentration (testosterone is secreted by Leydig cells) is lower in older (> 30 yr) compared with younger men with varicocele, which is a trend not seen in men without varicocele and suggests a progressive, adverse effect of varicocele on Leydig cell function.⁴

MacLeod (1965) and other investigators observed that most semen samples from infertile men with varicocele have poorer sperm parameters (lower sperm counts, increased number of spermatozoa with abnormal forms and decreased sperm motility) than fertile men.^{4,23,36} However, this “stress pattern” is not a specific marker for varicocele and therefore is not diagnostic of this condition.³⁷ Surprisingly, few studies have been conducted over the past 40 years to better define the pathophysiology of varicocele, in particular, the effect of this prevalent condition on human sperm function. This is especially critical in light of the inherent limitations (e.g., high biological variability) and modest predictive value of the standard sperm parameters in terms of reproductive outcomes.^{38,39}

Varicolectomy: approaches

There are several approaches for varicolectomy. These include retroperitoneal and conventional inguinal open techniques, microsurgical inguinal and subinguinal approaches, laparoscopic repairs and radiographic embolization.^{40–44} The microsurgical varicolectomy is considered the “gold standard” because it is associated with the lowest risk of complications (varicocele recurrence, hydrocele formation [fluid collection around the testicle] and testicular atrophy).^{41,45–47}

We have favoured the microsurgical subinguinal approach because it is associated with a higher success rate (disappearance of varicocele) and a lower complication rate (recurrence rate and hydrocele formation), compared with non-microsurgical techniques.^{46,48} The subinguinal approach is also associated with less operative and postoperative pain than inguinal approaches.^{49,50} However, the subinguinal approach is more challenging owing to the greater number of vessels (arteries and veins) encountered at this level, compared with the inguinal canal.⁵¹

Microsurgical sub-inguinal varicolectomy

We start with a 2–3-cm oblique skin incision centred over the external inguinal ring, as previously described.⁵² The incision is deepened through Camper’s and Scarpa’s fascias and the spermatic cord is then grasped with a Babcock clamp, delivered and placed over a large (1-inch) Penrose drain. The testicle is then delivered and the gubernacular veins and external spermatic perforators are isolated and divided (Fig. 1). The testicle is returned to the scrotum and the spermatic cord is elevated on a large Penrose drain. The microscope is then brought into the operating field and the cord examined under 8–15 power magnification. The internal and external spermatic fascias are incised and the cord structures are again examined (Fig. 2).

To simplify the procedure and protect the vas deferens and its vessels from potential injury dur-

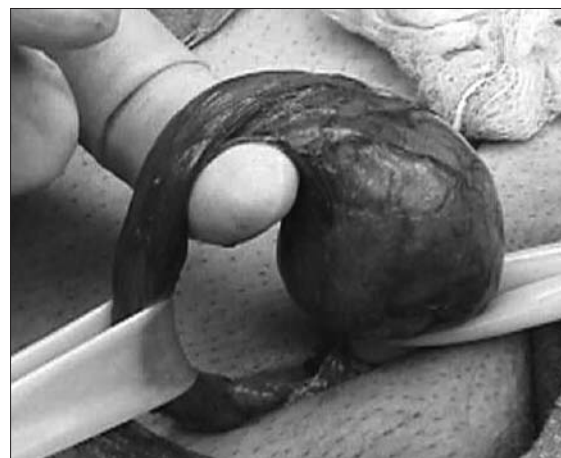

Fig. 1. Testicle delivered through the subinguinal incision depicting the spermatic cord (held by Penrose drain; bottom left) and the gubernaculum (held by Penrose drain; right).

ing subsequent cord dissection, we first create a window between the internal spermatic vessels and the external spermatic fascia so that the internal spermatic vessels are separate from the external spermatic fascia and its associated structures (cremasteric fibres, external spermatic vessels, vas deferens and its vessels).⁵² A second Penrose drain is then introduced between the internal spermatic vessels and the external spermatic fascia and its associated structures.

We first dissect the contents of the internal spermatic fascia (lying on top of the most superficial Penrose drain). Subtle pulsations will usually reveal the location of the underlying internal spermatic artery (or arteries). Once identified, the artery is dissected free of all surrounding veins and encircled with a 2-0 silk ligature for identification. Care is taken to identify a number of lymphatics (usually 2–5 channels) and these are also encircled with a 2-0 silk ligature. All internal spermatic veins are clipped or ligated (with 4-0 silk) and divided. At the end of the first dissection, the cord is skeletonized so that only the identified artery (or arteries) and lymphatics are preserved.

We then elevate and dissect the contents of the external spermatic fascia (lying between the 2 Penrose drains). The vas deferens and its associated vessels are readily identified and preserved. Any cremasteric artery is also preserved. The remaining cremasteric fibres and veins are ligated and cut thus skeletonizing the cord. At the completion of varicocelectomy, the cord should contain only the testicular artery or arteries, vas deferens, and associated vessels and spermatic cord lymphatics. The wound is irrigated with 1% Neomycin irrigation, and Scarpa's and Camper's

fascia are closed with a single 3-0 chromic catgut suture. The incision is infiltrated with 0.5% Marcaine solution with epinephrine, and the skin is closed with a running 4-0 Vicryl subcuticular closure reinforced with Steri-Strips. A dry sterile dressing is applied.

Summary

A variety of approaches have been advocated for management of varicoceles but recent evidence supports the premise that the microsurgical technique is the “gold standard.”^{46,48} In a number of studies, it has been shown that microsurgical varicocelectomy (inguinal or subinguinal) is superior to non-microsurgical procedures with respect to the development of postoperative complications such as hydrocele or recurrence.^{41,46,47} Hydrocele formation is believed to be due to ligation of lymphatic channels and recurrence generally results from incomplete ligation of collateral venous channels.^{53,54} Magnification of the spermatic cord with the use of the operating microscope reduces the potential for development of such complications.^{41,46,47} However, microsurgical varicocelectomy, particularly the subinguinal approach, remains a technically challenging procedure that requires microsurgical expertise.

From the Division of Urology, Department of Surgery, Royal Victoria Hospital, McGill University, Montréal, Que.

This article has been peer reviewed.

Competing interests: None declared.

References

1. Clarke BG. Incidence of varicocele in normal men and among men of different ages. *JAMA* 1966;198:1121-2.
2. Lipshultz LI, Corriere JN. Progressive testicular atrophy in the varicocele patient. *J Urol* 1977;117:175.
3. Akbay E, Cayan S, Doruk E, et al. The prevalence of varicocele and varicocele-related testicular atrophy in Turkish children and adolescents. *BJU Int* 2000;86:490-3.
4. World Health Organization. The influence of varicocele on parameters of fertility in a large group of men presenting to infertility clinics. *Fertil Steril* 1992;57:1289-92.
5. Pinto KJ, Kroovand RL, Jarow JP. Varicocele related testicular atrophy and its predictive effect upon fertility. *J Urol* 1994;152:788-90.
6. Jarow JP. Effects of varicocele on male fertility. *Hum Reprod Update* 2001;7:59-64.
7. Kamischke A, Nieschlag E. Varicocele treatment in the light of evidence-based andrology. *Hum Reprod Update* 2001;7:65-9.
8. Sharlip ID, Jarow JP, Belker AM, et al. Best practice policies for male infertility. *Fertil Steril* 2002;77:873-82.
9. Evers JL, Collins JA. Assessment of efficacy of varicocele repair for male subfertility: a systematic review. *Lancet* 2003;361:1849-52.




Fig. 2. Spermatic cord with Penrose drain beneath it (the internal and external spermatic fascias have been opened).

10. Ficarra V, Cerruto MA, Liguori G, et al. Treatment of varicocele in subfertile men: The Cochrane Review—a contrary opinion. *Eur Urol* 2006;49:258-63.
11. Schlesinger MH, Wilets IF, Nagler HM. Treatment outcome after varicocelectomy: A critical analysis. *Urol Clin North Am* 1994;21:517-29.
12. Nilsson S, Edvinsson A, Nilsson B. Improvement of semen and pregnancy rate after ligation and division of internal spermatic vein: fact or fiction? *Br J Urol* 1979;51:591-6.
13. Madgar I, Weissenberg R, Lunenfeld B, et al. Controlled trial of high spermatic vein ligation for varicocele in infertile men. *Fertil Steril* 1995;63:120-4.
14. Nieschlag E, Hertle L, Fishedick A, et al. Update on treatment of varicocele: counselling as effective as occlusion of the vena spermatica. *Hum Reprod* 1998;13:2147-50.
15. Krause W, Muller HH, Schafer H, et al. Does treatment of varicocele improve male fertility? Results of the 'Deutsche Varikozelenstudie', a multicentre study of 14 collaborating centres. *Andrologia* 2002;34:164-71.
16. Kamal KM, Jarvi K, Zini A. Microsurgical varicocelectomy in the era of assisted reproductive technology: influence of initial semen quality on pregnancy rates. *Fertil Steril* 2001;75:1013-6.
17. Buschi AJ, Harrison RB, Brenbridge AN, et al. Distended left renal vein: CT/sonographic normal variant. *Am J Radiol* 1980;135:339-42.
18. Braedel HU, Steffens J, Ziegler M, et al. A possible ontogenic etiology for idiopathic left varicocele. *J Urol* 1994;151:62-6.
19. Scaramuzza A, Tavara R, Marchi A. Varicoceles in young soccer players. *Lancet* 1996;348:1180-1.
20. Zorgnotti AW, MacLeod J. Studies in temperature, human semen quality, and varicocele. *Fertil Steril* 1973;24:854-63.
21. Soyopol DC, Howards SS, Turner TT. Influence of surgically induced varicocele on testicular blood flow, temperature, and histology in adult rats and dogs. *J Clin Invest* 1981;68:39.
22. Goldstein M, Eid JF. Elevation of intratesticular and scrotal skin surface temperature in men with varicocele. *J Urol* 1989;142:743-5.
23. Ali JJ, Weaver DJ, Weinstein SH, et al. Scrotal temperature and semen quality in men with and without varicocele. *Arch Androl* 1990;24:215-9.
24. Wright EJ, Young GP, Goldstein M. Reduction in testicular temperature after varicocelectomy in infertile men. *Urology* 1997;50:257-9.
25. Mieuisset R, Bujan L, Plantavid M, et al. Increased levels of serum follicle-stimulating hormone and luteinizing hormone associated with intrinsic testicular hyperthermia in oligospermic infertile men. *J Clin Endocrinol Metab* 1989;68:419-25.
26. Lue YH, Lasley BL, Laughlin LS, et al. Mild testicular hyperthermia induces profound transitional spermatogenic suppression through increased germ cell apoptosis in adult cynomolgus monkeys (*Macaca fascicularis*). *J Androl* 2002;23:799-805.
27. Sarge KD, Bray AE, Goodson ML. Altered stress response in testis. *Nature* 1995;374:126.
28. Bedford JM. Effects of elevated temperature on the epididymis and testis: experimental studies. *Adv Exp Med Biol* 1991;286:19-32.
29. Shafik A, Bedeir GA. Venous tension patterns in cord veins in normal and varicocele individuals. *J Urol* 1980;123:383-5.
30. Zini A, Bucksman M, Berardinucci D, et al. The influence of clinical and subclinical varicocele on testicular volume. *Fertil Steril* 1997;68:671-4.
31. Dubin L, Hotchkiss RS. Testis biopsy in subfertile men with varicocele. *Fertil Steril* 1969;20:50-7.
32. Comhaire F, Vermeulen A. Plasma testosterone in patients with varicocele and sexual inadequacy. *J Clin Endocrinol Metab* 1975;40:824-9.
33. Johnsen SG, Agger P. Quantitative evaluation of testicular biopsies in varicocele. *Fertil Steril* 1978a;29:52-7.
34. Hudson RW. The endocrinology of varicoceles. *Fertil Steril* 1988;49:199-208.
35. Su LM, Goldstein M, Schlegel PN. The effect of varicocelectomy on serum testosterone levels in infertile men with varicoceles. *J Urol* 1995;154:1752-5.
36. Macleod J. Seminal cytology in the presence of varicocele. *Fertil Steril* 1965;16:735-57.
37. Ayodeji O, Baker HW. Is there a specific abnormality of sperm morphology in men with varicoceles? *Fertil Steril* 1986;45:839-42.
38. Guzik DS, Overstreet JW, Factor-Litvak P, et al; National Cooperative Reproductive Medicine Network. Sperm morphology, motility, and concentration in fertile and infertile men. *N Engl J Med* 2001;345:1388-93.
39. Menkveld R, Wong WY, Lombard CJ, et al. Semen parameters, including WHO and strict criteria morphology, in a fertile and subfertile population: an effort towards standardization of in-vivo thresholds. *Hum Reprod* 2001;16:1165-71.
40. Walsh PC, White RI. Balloon occlusion of the internal spermatic vein for the treatment of varicoceles. *JAMA* 1981;246:1701.
41. Goldstein M, Gilbert BR, Dicker AP, et al. Microsurgical inguinal varicocelectomy with delivery of the testis: An artery and lymphatic sparing technique. *J Urol* 1992;148:1808-11.
42. Donovan JF, Winfield HN. Laparoscopic varix ligation. *J Urol* 1992;147:77.
43. Jarow JP, Assimos DJ, Pittaway DE. Effectiveness of laparoscopic varicocelectomy. *Urology* 1993;42:544-7.
44. Enquist E, Stein BS, Sigman M. Laparoscopic versus subinguinal varicocelectomy: a comparative study. *Fertil Steril* 1994;61:1092-6.
45. Murray RR, Mitchell SE, Kadir S, et al. Comparison of recurrent varicocele anatomy following surgery and percutaneous balloon occlusion. *J Urol* 1986;135:286-9.
46. Cayan S, Kadioglu TC, Tefekli A, et al. Comparison of results and complications of high ligation surgery and microsurgical high inguinal varicocelectomy in the treatment of varicocele. *Urology* 2000;55:750-4.
47. Grober ED, O'Brien J, Jarvi KA, Zini A. Preservation of testicular arteries during subinguinal microsurgical varicocelectomy: clinical considerations. *J Androl* 2004;25:740-3.
48. Ghanem H, Anis T, El-Nashar A, et al. Subinguinal microvaricocelectomy versus retroperitoneal varicocelectomy: comparative study of complications and surgical outcome. *Urology* 2004;64:1005-9.
49. Gontero P, Pretti G, Fontana F, et al. Inguinal versus subinguinal varicocele vein ligation using magnifying loupe under local anesthesia: which technique is preferable in clinical practice? *Urology* 2005;66:1075-9.
50. Al-Kandari AM, Shabaan H, Ibrahim HM, et al. Comparison of outcomes of different varicocelectomy techniques: open inguinal, laparoscopic, and subinguinal microscopic varicocelectomy: a randomized clinical trial. *Urology* 2007;69:417-20.
51. Hopps CV, Lemer ML, Schlegel PN, et al. Intraoperative varicocele anatomy: a microscopic study of the inguinal versus subinguinal approach. *J Urol* 2003;170:2366-70.
52. Zini A, Fischer MA, Bellock D, et al. Technical modification of microsurgical varicocelectomy can reduce operating time. *Urology* 2006;67:803-6.
53. Kaufman SL, Kadir S, Barth KH, et al. Mechanisms of recurrent varicocele after balloon occlusion or surgical ligation of the internal spermatic vein. *Radiology* 1983;147:435-40.
54. Szabo R, Kessler R. Hydrocele following internal spermatic vein ligation: A retrospective study and review of the literature. *J Urol* 1984;132:924-5.

Correspondence: Dr. Armand Zini, St. Mary's Hospital, 3830 Lacombe Ave., Montréal QC H3T 1M5; ziniarmand@yahoo.com

Varicocelectomy: microsurgical inguinal varicocelectomy is the treatment of choice

Saleh Binsaleh, MD; Kirk C. Lo, MD

Introduction

Varicocelectomy is by far the most commonly performed operation for the treatment of male infertility. The goal of treatment of the varicocele is to obstruct the refluxing venous drainage to the testis while maintaining arterial inflow and lymphatic drainage.

In principle, repair of varicocele should halt any further damage to testicular function,¹ and in a large percentage of men, results in improved spermatogenesis² as well as enhanced Leydig cell function.³ Urologists, therefore, have a potentially important role in preventing future infertility, which underscores the importance of using a varicocelectomy technique that minimizes the risk of complications and recurrence.⁴

A variety of surgical and nonsurgical approaches have been advocated for varicocelectomy. They include minimally invasive procedures, such as laparoscopic varicocelectomy and transvenous percutaneous embolization, and the traditional open surgical approach (retroperitoneal, inguinal and subinguinal). The current standard of care is to perform open surgical varicocele repair with microscopic assistance to minimize possible complications.

In this section, we discuss the microsurgical inguinal approach as the treatment of choice for varicocele ligation.

Inguinal microsurgical approach

Inguinal approach is the modification of the technique described by Ivanissevich and Gregorini in 1918. The inguinal approach involves a 3–5-cm incision over the inguinal canal, the opening of the external oblique aponeurosis and the delivery of the spermatic cord. The cord is elevated and any external spermatic veins that are running parallel to the spermatic cord or perforating the floor of the inguinal canal are identified and ligated. All internal spermatic veins are identified

and dissected under microscopy and then ligated with sutures or surgical clips. The vas deferens, vasal vessels, testicular artery (or arteries) and as many lymphatic channels as possible are preserved. Postoperatively, testicular venous return is via the vasal veins, which drain into the internal pudendal system and usually have competent valves.⁴

Compared with inguinal approach, the use of subinguinal approach is associated with a greater number of internal spermatic veins and arteries requiring attention. Hopps and colleagues⁵ confirmed this microanatomy variation and its impact on the surgical technique. The primary branch point for the testicular artery occurred most commonly during its course through the inguinal canal. Internal spermatic arteries at the subinguinal level were more than 3 times as likely to be surrounded by a dense network of adherent veins than when they were identified at the inguinal level. Taken together, these data suggest that microscopic dissection is more difficult with a subinguinal incision. Similarly, identification of testicular artery pulsation can be difficult in the subinguinal approach owing to arterial compression by the edge of the external ring against elevated cord, compared with when the external oblique aponeurosis is opened.⁶ Artery identification is crucial in every patient, and even more so in children or prepubertal adolescents in whom the artery is very small and systemic blood pressure is low. Inguinal approach should also be the first choice in men with a solitary testis in whom preservation of the artery is critical.⁶

Delivery of the testis for direct visual access to all possible avenues of testicular venous drainage (scrotal or gubernacular collaterals) or for concomitant diagnostic testicular biopsy is possible through a small inguinal incision⁴; however, others found that varicocelectomy without testicular delivery has equal or greater beneficial effects on semen parameters without affecting

varicocele recurrence rates or pregnancy rates after varicocelectomy.⁷

There are few studies that compare head to head the 2 open approaches using microsurgical technique. A group of researchers from Italy⁸ compared the intraoperative results of inguinal versus subinguinal varicocelectomy using a magnifying loupe under local anesthesia. The inguinal approach to the spermatic cord showed a trend toward an easier preservation of the artery and a reduced incidence of recurrence, while postoperative pain was significantly lower in the subinguinal group. Orhan and colleagues⁹ retrospectively evaluated 82 microsurgical inguinal varicocelectomies and 65 subinguinal cases. There was no significant difference between the 2 groups in operative time, semen improvement or pregnancy rate, although the number of veins and arteries was higher in the subinguinal group.

Finally, open microsurgical varicocelectomy has a lower recurrence rate and fewer complications, compared with laparoscopic varicocelectomy or retroperitoneal high-open ligation.¹⁰⁻¹²

In conclusion, inguinal varicocelectomy is the original approach and the standard against which others should be compared. Except in limited situations, such as previous inguinal surgery or marked obesity that hinders dissection, microsurgical inguinal varicocelectomy should be the treatment of choice.

From the Division of Urology, Department of Surgery, Murray Koffler Urologic Wellness Centre, Mount Sinai Hospital, University of Toronto, Toronto, Ont.

This article has been peer reviewed.

Competing interests: None declared.

References

1. Kass EJ, Chandra RS, Belman AB. Testicular histology in the adolescent with a varicocele. *Pediatrics* 1987;79:996-8.
2. Dubin L, Amelar R. Varicocelectomy: 986 cases in a 12 year study. *Urology* 1977;10:446-9.
3. Su L-M, Goldstein M, Schlegel PN. The effect of varicocelectomy on serum testosterone levels in infertile men with varicoceles. *J Urol* 1995;154:1752-5.
4. Goldstein M, Gilbert BR, Dicker AP, et al. Microsurgical inguinal varicocelectomy with delivery of the testis: an artery and lymphatic sparing technique. *J Urol* 1992;148:1808-11.
5. Hopps CV, Lemer ML, Schlegel PN, et al. Intraoperative varicocele anatomy: a microscopic study of the inguinal versus subinguinal approach. *J Urol* 2003;170:2366-70.
6. Goldstein M. Surgical management of male infertility and other scrotal disorders. In *Campbell's Urology*, 8th edition. Walsh PC, Retik AB, Vaughan ED, Wein AJ, eds. Philadelphia: W.B. Saunders; 2002. p 1573-4.
7. Ramasamy R, Schlegel PN. Microsurgical inguinal varicocelectomy with and without testicular delivery. *Urology* 2006;68:1323-6.
8. Gontero P, Pretti G, Fontana F, et al. Inguinal versus subinguinal varicocele vein ligation using magnifying loupe under local anesthesia: Which technique is preferable in clinical practice? *Urology* 2005;66:1075-9.
9. Orhan I, Onur R, Semercioz A, et al. Comparison of two different microsurgical methods in the treatment of varicocele. *Arch Androl* 2005;51:213-20.
10. Al-Kandari AM, Shabaan H, Ibrahim HM, et al. Comparison of outcomes of different varicocelectomy techniques: open inguinal, laparoscopic, and subinguinal microscopic varicocelectomy: a randomized clinical trial. *Urology* 2007;69:417-20.
11. Watanabe M, Nagai A, Kusumi N, et al. Minimal invasiveness and effectiveness of subinguinal microscopic varicocelectomy: a comparative study with retroperitoneal high and laparoscopic approaches. *Int J Urol* 2005;12:892-8.
12. Hirsch IH, Abdel-Meguid TA, Gomella LG. Postsurgical outcomes assessment following varicocele ligation: laparoscopic versus subinguinal approach. *Urology* 1998;51:810-5.

Correspondence: Dr. Kirk C. Lo, Division of Urology, Department of Surgery, Murray Koffler Urologic Wellness Centre, 60 Murray St., 6th Fl., Toronto ON M5G 1X5; klo@mtsina.on.ca

Percutaneous varicocele embolization

J. Robert D. Beecroft, BSc, MD, FRCPC

Introduction

The treatment of varicocele by percutaneous embolization of the internal spermatic vein is a safe and effective minimally invasive procedure. Its very low morbidity and complication rates, high long-term success rates and demonstrated cost effectiveness relative to surgery have led some authors to argue that percutaneous embolic tech-

niques should be the primary therapy to treat varicoceles, or at least a viable and valuable alternative to surgical options.¹⁻⁵

Technique

Percutaneous embolization of varicocele requires selective catheterization of the internal spermatic vein(s) followed by its occlusion with either a

sclerosant or solid embolic devices.⁶ Although many devices and agents have been described for this purpose, current techniques use predominantly coils (stainless steel or platinum) as the solid embolic agent, sodium tetradecyl sulfate as the sclerosant or a combination of the 2.

The procedure is performed on an outpatient basis under local anesthesia. Conscious sedation with titrated doses of intravenous midazolam and fentanyl can be used if required. The patient is placed supine on the angiography table, and gonads shielded from irradiation. Aseptic conditions are used. The procedure is performed from internal jugular or common femoral venous approaches; the selected access vein is punctured under ultrasound guidance. Using the Seldinger technique, an appropriate catheter (typically 5–7 Fr in size) is used to select the left renal vein. Some interventional radiologists advocate initial left renal venography to demonstrate reflux of contrast into left internal spermatic vein due to incompetent valves and to delineate potential collateral pathways, while others proceed to selection of the left or right internal spermatic vein and internal spermatic venography. The catheter is advanced retrogradely down the internal spermatic vein to just above the inguinal ligament level. Venography is performed to document the position of the catheter before commencing embolization, as well as assess the size of the internal spermatic vein and the presence of any collateral circulation.

If coils are being used, embolization is commenced at this level, with additional coils deployed in the more cephalad internal spermatic vein extending to near its junction with the left renal vein or inferior vena cava (for right internal spermatic vein) so that the coils occlude the main branch and all accessible collaterals. To minimize the risk of recurrence, it is necessary to isolate the most distal (caudal) segment of the internal spermatic vein from any potential collateral supply. In some patients, collateral parallel channels must be selectively catheterized and occluded.

When sclerosants are used, the technique is similar, with care taken to apply external pressure at the inguinal crease when injecting the sclerosant to prevent reflux into the pampiniform plexus. The Trendelenburg position can also be used to decrease the risk of reflux into the pampiniform venous plexus.

If a combination of coils and sclerosant are

being used (referred to, by some, as the “sandwich” technique), coils are placed in the distal internal spermatic vein just above the inguinal ligament level. The purpose of the coils is to prevent reflux of sclerosant into the pampiniform plexus, and is in addition to the previously described manoeuvres. Sclerosant is then injected slowly along the length of the internal spermatic vein while withdrawing the catheter, followed by placing coils in the cephalad internal spermatic vein.

Postprocedure hemostasis is achieved at the puncture site with manual compression. The patient is observed for approximately 2–3 hours post procedure before being discharged home. Patients are typically able to return to work the following day, but are advised to avoid heavy lifting and contact sports for 5–7 days.

Results

In recently published studies, technical success rates are 92.4%⁷–96%.⁸ Recurrence rates are < 2%⁸–4%⁹ among those referred for infertility. In the pediatric and adolescent population, long-term recurrence rates in those for whom the procedure was initially technically successful are as low as 7%⁵ and 11%.¹⁰ Most of the patients in the quoted studies have unilateral left-sided varicoceles, though right-sided varicoceles are included in the results. The rates of technical success and recurrence rates in the recent literature have improved, compared with previously published studies in the 1980s and early 1990s. This is owing to improvements in techniques, increasing expertise in the area and improved equipment including catheters, coils and contrast media.⁸

With regard to outcomes in the treatment of varicoceles in the infertile or subfertile population, the improvements in seminal parameters and pregnancy outcomes are equivalent in patients who have undergone percutaneous embolization versus surgical ligation.^{3,9,11} Reyes and colleagues found the long-term success and complication rates of percutaneous embolization of adolescent varicocele comparable to those with surgical ligation.⁵

The complications of percutaneous therapy are infrequent and typically mild.¹² Complication rates in recent literature have been reported from 0%,⁸ to 5%⁵ and 11%.⁹ Thrombophlebitis of the pampiniform plexus is a potential complication when sclerosants are used; Wunsch and colleagues

report its occurrence in 0.5% of cases,¹ and it requires treatment with anti-inflammatories and antibiotics. It is prevented by compression at the inguinal crease or by using coils at the outset. Coil migration is a rare complication that is always linked to excessively distal release. Reported cases to date have been asymptomatic.⁶ Hydrocele and testicular atrophy are not potential complications with embolization techniques.

Exposure to ionizing radiation during image guided percutaneous therapy is a potential concern given the procedure is typically performed on healthy young males with normal life expectancy and the future potential to reproduce.¹³ Studies have shown that if proper techniques are used (shielding the gonads, avoiding exposure of the scrotum to the primary beam, collimation of beam to smallest practical area, and using pulsed fluoroscopy and image capture to minimize angiographic runs and spot images), doses are within the range of other diagnostic procedures such as CT scan, and gonadal dose values are low enough to exclude induction of deterministic and hereditary effects.⁷

Benefits

The benefits of percutaneous embolic therapy for varicocele extend beyond its high technical and clinical success rates, equivalency to surgical therapies in terms of outcomes and very low complication rates. It is a minimally invasive, outpatient procedure that allows quick patient recovery, minimal discomfort compared with surgery, and shorter time to return to work (typically within 1–2 d) and full activities.³ It is cost effective relative to surgery in that the procedural costs are less or similar, but embolization has the financial advantage in that shorter recovery time minimizes inconvenience and loss of potential working days.³ Feneley and colleagues showed that patients who underwent both embolization and surgical ligation expressed a strong preference for embolization.² Additional advantages to the embolization approach are that bilateral varicoceles can be treated at a single setting via the same venous access, and that it has a high technical success rate in treating recurrent varicoceles post surgical ligation.⁵

Conclusion

Percutaneous embolization of the internal sper-

matic vein to treat varicoceles is a minimally invasive outpatient procedure that, when performed by experienced interventional radiologists, has high technical success rates, low recurrence rates, very low morbidity and minimal radiation. It has been demonstrated to be equal to surgical ligation in clinical results and as or more cost effective. Its minimally invasive nature allows it be well tolerated with shorter recovery times and less discomfort relative to surgery. When skilled and experienced vascular and interventional radiology services are available, embolization is an effective alternative to surgery and should be offered as such or as primary therapy for varicocele treatment.

From the Division of Vascular and Interventional Radiology, Department of Medical Imaging, University Health Network, Mount Sinai Hospital, Toronto, Ont.

This article has been peer reviewed.

Competing interests: None declared.

References

1. Wunsch R, Efinger K. The interventional therapy of varicoceles amongst children, adolescents, and young men. *Eur J Radiol* 2005;53:46-56.
2. Feneley MR, Pal MK, Nockler IB, et al. Retrograde embolization and causes of failure in the primary treatment of varicocele. *Br J Urol* 1997;80:642-6.
3. Dewire DM, Thomas AJ, Falk RM, et al. Clinical outcome and cost comparison of percutaneous embolization and surgical ligation of varicocele. *J Androl* 1994;15:385-425.
4. Lenk S, Fohlenkamp D, Glied V, et al. Comparison of different methods of treating varicocele. *J Androl* 1994;15:345-75.
5. Reyes BL, Trerotola SO, Venbrux AC, et al. Percutaneous embolotherapy of adolescent varicocele: results and long term follow-up. *J Vasc Interv Radiol* 1995;5:131-4.
6. Cornud F, Belin X, Amar E, et al. Varicocele: strategies in diagnosis and treatment. *Eur Radiol* 1999;9:536-45.
7. Gazzera C, Rampado O, Savio L, et al. Radiological treatment of male varicocele: technical, clinical, seminal, and dosimetric aspects. *Radiol Med (Torino)* 2006;111:449-58.
8. Nabi G, Asterlings S, Greene DR, et al. Percutaneous embolization of varicoceles: outcomes and correlation of semen improvement with pregnancy. *Urology* 2004;63:359-63.
9. Shlansky-Goldberg RD, VanArsdalen KN, Rutter CM, et al. Percutaneous varicocele embolization versus surgical ligation for the treatment on infertility: changes in seminal parameters and pregnancy outcomes. *J Vasc Interv Radiol* 1997;8:759-67.
10. Alqahtani A, Yazbeck S, Dubois J, et al. Percutaneous embolization of varicocele in children: a Canadian experience. *J Pediatr Surg* 2002;37:783-5.
11. Nieschlag E, Behre HM, Schlingheider A, et al. Surgical ligation vs. angiographic embolization of the vena spermatica: a prospective randomized study for the treatment of varicocele-related infertility. *Andrologia* 1993;25:233-7.
12. Practice committee of the American Society for reproductive Medicine. Report on varicoceles and infertility. *Fertil Steril* 2006;86:S93-5.
13. Chalmers N, Hufton AP, Jackson AW, et al. Radiation risk estimation in varicocele embolization. *Br J Radiol* 2000;73:293-7.

Correspondence: Dr. J.R. Beecroft, Rm. 575, Department of Medical Imaging, Mount Sinai Hospital, 600 University Ave., Toronto ON M5G 1X5; Rob.Beecroft@uhn.on.ca

Dr. Zini's rebuttal

Varicocele repair is indicated for the management of clinical varicocele associated with male infertility, testicular pain or testicular atrophy (in the child or adolescent). There are several approaches for the management of clinical varicoceles (retroperitoneal and conventional inguinal techniques, microsurgical inguinal and subinguinal approaches, laparoscopic repairs and radiographic embolization), each associated with variable success and complication rates. The cure and complication rate of varicocele repair depends on the specific technique as well as on the expertise of the clinician or surgeon performing the procedure. Therefore, before proceeding to varicocele repair, the clinician should discuss with the patient the various techniques, the availability of these techniques (locally and abroad), and the cure and complication rates associated with the techniques (locally and abroad). The patient can then make an informed decision regarding varicocele repair.

The microsurgical varicocelectomy is considered the "gold standard" because it is associated with the lowest risk (< 1% risk) of complications (varicocele recurrence, hydrocele formation [fluid collection around the testicle] and testicular atrophy).¹⁻⁴ Hydrocele formation is believed to be due to ligation of lymphatic channels, and recurrence generally results from incomplete ligation of collateral venous channels.^{5,6} Magnification of the spermatic cord with the use of the operating microscope reduces the potential for development of such complications.¹⁻⁴ However, it is clear that this technically challenging procedure requires substantial microsurgical expertise. We have favoured the microsurgical subinguinal approach because it

is also associated with less operative and post-operative pain than inguinal approaches.^{7,8} However, the subinguinal approach is even more challenging owing to the greater number of vessels (arteries and veins) encountered at this level, compared with that encountered at the level of the inguinal canal.⁹ As such, we recognize that the more novice microsurgeon should perhaps initially adopt the inguinal approach and only with substantial expertise switch to the subinguinal approach.

This article has been peer reviewed.

Competing interests: None declared.

References

1. Goldstein M, Gilbert BR, Dicker AP, et al. Microsurgical inguinal varicocelectomy with delivery of the testis: An artery and lymphatic sparing technique. *J Urol* 1992;148:1808-11.
2. Murray RR, Mitchell SE, Kadir S, et al. Comparison of recurrent varicocele anatomy following surgery and percutaneous balloon occlusion. *J Urol* 1986;135:286-9.
3. Cayan S, Kadioglu TC, Tefekli A, et al. Comparison of results and complications of high ligation surgery and microsurgical high inguinal varicocelectomy in the treatment of varicocele. *Urology* 2000;55:750-4.
4. Grober ED, O'Brien J, Jarvi KA, Zini A. Preservation of testicular arteries during subinguinal microsurgical varicocelectomy: clinical considerations. *J Androl* 2004;25:740-3.
5. Kaufman SL, Kadir S, Barth KH, et al. Mechanisms of recurrent varicocele after balloon occlusion or surgical ligation of the internal spermatic vein. *Radiology* 1983;147:435-40.
6. Szabo R, Kessler R. Hydrocele following internal spermatic vein ligation: a retrospective study and review of the literature. *J Urol* 1984;132:924-5.
7. Gontero P, Pretti G, Fontana F, et al. Inguinal versus subinguinal varicocele vein ligation using magnifying loupe under local anesthesia: which technique is preferable in clinical practice? *Urology* 2005;66:1075-9.
8. Al-Kandari AM, Shabaan H, Ibrahim HM, et al. Comparison of outcomes of different varicocelectomy techniques: open inguinal, laparoscopic, and subinguinal microscopic varicocelectomy: a randomized clinical trial. *Urology* 2007;69:417-20.
9. Hopps CV, Lemer ML, Schlegel PN, et al. Intraoperative varicocele anatomy: a microscopic study of the inguinal versus subinguinal approach. *J Urol* 2003;170:2366-70.

Dr. Lo's rebuttal

Dr. Zini described the microsurgical subinguinal technique in the treatment of varicocele and Dr. Beecroft highlighted the advantage of percutaneous varicocele embolization comparing it with the surgical approaches. The arguments from both articles are sound based on their selected references. However, there are a few issues, such as the learning curve for the challenging subinguinal techniques and the long-term effect of radiation exposure during embolization, that should not be overlooked.

With the aid of the surgical microscope, both inguinal and subinguinal approaches achieve similar results in terms of improvement in semen parameters and low complication and recurrence rates. However, the complexity of the spermatic arteries and veins at the subinguinal level lends itself to potential arterial injury resulting in permanent damage to the testis. Even in expert hands, the risk of accidental arterial ligation using the subinguinal method is about 1%.¹ Extensive training in this technique is required to ensure safe and proper treatment for the patient undergoing this elective procedure.

Percutaneous embolization of the varicocele appears to be a promising alternative with its "non-invasive" nature and quicker recovery post-treatment. The recurrence rate has also been decreasing with modern equipment, catheters and coils. Nevertheless, the major criticism of this technique has been the relatively high rate of unperforable procedures ranging from 8% to 15%.²⁻⁴ It is particularly difficult to gain access

to right-sided varicoceles owing to their anatomic variations. The discrepancy in the literature concerning the recurrence and failure rate may be operator dependent as well. Dr. Beecroft briefly mentioned the radiation exposure during the procedure. Although care can be taken to minimize radiation dosage, the long-term effect is still not well established.

Overall, there are pros and cons for each technique described in this series of debates. Patients should be informed of the options and their potential benefits and risks. In my opinion, the microsurgical inguinal technique has the advantage of easier identifiable anatomic vasculature, hence a shorter learning curve and lower risk of arterial damage. Surgical varicocele repair also offers a more direct approach with respect to isolation and ligation of the spermatic veins, especially in patients with bilateral varicocele.

This article has been peer reviewed.

Competing interests: None declared.

References

1. Chan PT, Wright EJ, Goldstein M. Incidence and postoperative outcomes of accidental ligation of the testicular artery during microsurgical varicocelectomy. *J Urol* 2005;173:482-4.
2. Lenz M, Hof N, Kersting-Sommerhoff B, et al. Anatomic variants of the spermatic vein: importance for percutaneous sclerotherapy of idiopathic varicocele. *Radiology* 1996;198:425-31.
3. Porst H, Bahren W, Lenz M, et al. Percutaneous sclerotherapy of varicoceles — an alternative to conventional surgical methods. *Br J Urol* 1984;56:73-8.
4. Puneekar SV, Prem AR, Ridhorkar VR, et al. Post-surgical recurrent varicocele: efficacy of internal spermatic venography and steel-coil embolization. *Br J Urol* 1996;77:124-8.

BROCHURES INFO-PATIENTS DE L'AUC



Soins du cathéter urétral



Des soins appropriés du cathéter réduiront l'inconfort et préviendront les complications.

Offerts gratuitement aux membres actifs, seniors et honoraires en règle avec l'AUC

Pour obtenir plus de renseignements, contacter l'AUC à :

Tél. : 514 395-0376

Télec. : 514 875-0205

Courriel : brochures@cua.org

Les bons de commande sont disponibles à :
www.cua.org

Choisir de 50 sujets – ci-dessous :

Général

Cathétérismes intermittents propres pour les hommes
Cathétérismes intermittents propres pour les femmes
Cystoscopie
Cystoscopie - Instructions après l'intervention
Hématurie
La chirurgie laparoscopique et l'urologie
Les soins palliatifs pour une vie de qualité
Soins du cathéter urétral
Bilan dynamique
Calendrier mictionnel

Pédiatrique

L'incontinence urinaire nocturne
Circoncision chez l'enfant
Circoncision chez l'enfant - Instructions après l'intervention
Troubles de l'élimination chez les enfants
Soins de la prépuce chez les garçons
Testicule non descendu
Le reflux vésico-urétéral

La vessie

Traitement de BCG pour le cancer de la vessie
Les infections de la vessie chez la femme
Tumeur de la vessie
Résection de tumeur vésicale
Cystite interstitielle
Vessie hyperactive
L'incontinence urinaire à l'effort

La prostate

Thérapie hormonale pour cancer de la prostate
Échographie et biopsies de la prostate
Prostatectomie radicale - Instructions après l'intervention
Prostatectomie radicale rétropubienne
Radiothérapie pour le cancer de la prostate
Résection trans-urétrale de la prostate
Résection trans-urétrale de la prostate - Instructions après l'intervention

Infertilité/sexualité

Dysfonction érectile - options de traitement
Traitement androgénique
La maladie de la Peyronie

Le rein/l'uretère

Calculs rénaux
Les tumeurs rénales
Néphrolithotomie percutanée
Colique néphrétique
Lithotritie par ondes de choc pour pierres aux reins
Lithotritie par ondes de choc - Instructions après l'intervention
Mise en place de sonde urétérale
Obstruction de la jonction urétéro-pyélique
L'urétéroscopie

Génital

La douleur scrotale
Chirurgie scrotale - Instructions après l'intervention
Tuméfactions scrotales
Les sténoses urétrales chez les hommes
Vasectomie
Vasectomie - Instructions après l'intervention
Vasovasostomie



Veillez cocher (✓) le titre et le nombre de brochures de l'AUC que vous désirez recevoir. Pour télécharger ce bon de commande, rendez-vous au site www.cua.org et cliquez sur l'icône « information au patients ».

Urologue(s) : _____

Numéro(s) de membre AUC : _____

Adresse : _____

Ville : _____ Prov : _____

Code Postal : _____

Brochures info-patients de l'AUC			Anglais		Français	
			50	100	50	100
Général	1	Cathétérismes intermittents propres pour les hommes				
	2	Cathétérismes intermittents propres pour les femmes				
	3	Cystoscopie				
	4	Cystoscopie - instr. après interv.				
	5	Hématurie				
	6	La chirurgie laparoscopique et l'urologie				
	7	Les soins palliatifs pour une vie de qualité				
	8	Soins du cathéter urétral				
	9	Bilan urodynamique				
	10	Calendrier mictionnel				
Pédiatrique	11	L'incontinence urinaire nocturne				
	12	Circoncision chez l'enfant				
	13	Circoncision chez l'enfant - instr. après interv.				
	14	Troubles de l'élimination chez les enfants				
	15	Soins du prépuce chez les garçons				
	16	Testicule non descendu				
	17	Le reflux vésico-urétéral				

			Anglais		Français	
			50	100	50	100
Rein / Urètre	35	Calculs rénaux				
	36	Les tumeurs rénales				
	37	Néphrolithotomie percutanée				
	38	Colique néphrétique				
	39	Lithotritie par ondes de choc pour pierres aux reins				
	40	Lithotritie par ondes de choc - instr. après interv.				
	41	Mise en place de sonde urétérale				
	42	Obstruction de la jonction urétéro-pyélique				
	43	L'urétéroscopie				
	Génital	44	La douleur scrotale			
45		Chirurgie scrotale - instr. après interv.				
46		Tuméfactions scrotales				
47		Les sténoses urétrales chez les hommes				
48		Vasectomie				
49		Vasectomie - instr. après interv.				
50		Renversement de vasectomie				

			Anglais		Français	
			50	100	50	100
Vessie	18	Traitement de BCG pour le cancer de la vessie				
	19	Les infections de la vessie chez la femme				
	20	Tumeur de la vessie				
	21	Résection de tumeur vésicale				
	22	Cystite interstitielle				
	23	Vessie hyperactive				
Prostate	24	L'incontinence urinaire à l'effort				
	25	Thérapie hormonale pour cancer de la prostate				
	26	Échographie et biopsies de la prostate				
	27	Radiothérapie pour le cancer de la prostate				
	28	Prostatectomie radicale rétropubienne				
	29	Prostatectomie radicale - instr. après interv.				
Sexualité / Infertilité	30	Résection trans-urétrale de la prostate				
	31	Résection trans-urétrale de la prostate - instr. après interv.				
	32	Dysfonction érectile - options de traitement				
	33	Supplément hormonal chez l'homme vieillissant				
	34	Maladie de la Peyronie				

**Conseil canadien sur les maladies de la prostate
Brochures info-patients**

Titres disponibles			Anglais		Français	
			25	50	25	50
51	Hypertrophie bénigne de la prostate					
52	Prévention du cancer de la prostate					
53	Antigène prostatique spécifique					
54	Cancer de la prostate					
55	Prostatite					

Notes supplémentaires :

Pour tout renseignement, veuillez communiquer avec nous par :

Téléphone : 514 395-0376

Télocopieur : 514 875-0205

Courriel : brochures@cua.org